

经皮椎体成形术骨水泥“倒U型”分布的临床疗效

黄 荷, 张兆飞, 谢春亮, 刘栋华
(广州市中西医结合医院骨科, 广东 广州 510800)

摘要:【目的】探讨椎体成形术(PVP)中骨水泥在椎体内呈“倒U型”分布的临床疗效。【方法】回顾性分析我院从2009年6月至2016年8月间行单一椎体PVP(低黏度骨水泥)手术的患者,根据X线及CT骨水泥的分布情况分为两组。A组:完整的“倒U型”分布(椎体前缘有骨水泥连接);B组:未形成完整的“倒U型”分布(椎体前缘无骨水泥连接)。评价术前、术后3d,末次随访的视觉模拟评分(VAS)、Oswestry功能障碍指数(ODI)、局部后凸(Cobb)角,随访中间的相邻椎体骨折也被评价。【结果】83个行低黏度骨水泥PVP手术的患者纳入我们的研究,包括37个“倒U型”分布和46个不完整“倒U型”分布的椎体,随访时间1~2年。所有患者术后3d疼痛均较术前明显缓解($P<0.05$),A组术后3dVAS较B组缓解更为显著($P<0.05$),末次随访两组差异无统计学意义($P>0.05$)。两组ODI结果和VAS评分结果相似。术后3d局部Cobb角两组均较术前改善($P<0.05$),两组末次随访局部Cobb角均未见明显丢失($P>0.05$)。A组和B组分别出现了2和4例相邻椎体骨折,提示差异无统计学意义($P>0.05$)。【结论】骨水泥在椎体内呈“倒U型”分布是影响PVP临床疗效的因素之一,尤其是在术后疼痛快速缓解方面。另外,骨水泥在椎体侧壁和前柱的充填非常重要,它是预防椎体再塌陷的重要因素之一。

关键词:经皮椎体成形术;倒U型;水泥分布

中图分类号:R683.2 文献标志码:A 文章编号:1672-3554(2018)04-0554-06

Clinical Effect of Bone Cement Distribution of “Inverted U” Type in the Injured Vertebral Body in Percutaneous Vertebroplasty Procedure

HUANG He, ZHANG Zhao-fei, XIE Chun-liang, LIU Dong-hua

(Department of Orthopedic Surgery, Guangzhou Hospital of Integrated Traditional and West Medicine, Guangzhou 510800, China)

Corresponding to: HUANG He, E-mail: huanghezhen@163.com

Abstract: 【Objective】 To investigate clinical effect of bone cement distribution of “inverted U” style in the injured vertebral body in percutaneous vertebroplasty (PVP) procedure. 【Methods】 From June 2009 to August 2016, the patients who underwent PVP using low-viscosity cement for treating single vertebral fracture were reviewed in our hospital. The patients were divided into two groups according to CT and X-ray image of bone cement distribution. Group A: bone cement was presented as a complete “inverted U” type in the vertebral body (the bone cement was interconnected at the anterior edge of vertebral body); group B: A complete “inverted U” type distribution was unformed (the bone cement was not interconnected at the anterior edge of vertebral body). The data about visual analogue scale (VAS), Oswestry Disability Index (ODI) and Cobb angle before operation, at the 3rd day after operation, and at the final follow-up were collected and evaluated. Adjacent vertebral fracture was also evaluated during the follow-up. 【Results】 Eighty-three patients who had PVP procedures with low-viscosity cement, including 37 vertebrae with “inverted U” type distribution and 46 vertebrae with incomplete “inverted U” type distribution, were reviewed in our study. The follow-up was 1 to 2 years. The patients' pain in both groups were obviously relieved at the 3rd day after operation ($P<0.05$). The VAS in the A group was more lower than that in the B group ($P<0.05$). There was no difference at the final follow-up between the two groups ($P>0.05$). A similar result occurred for ODI between them. The Cobb angle at the post-operation 3rd day in both

收稿日期:2018-02-21

作者简介:黄荷,通信作者:医学博士,副主任医师,研究方向:脊柱骨病的诊治,E-mail: huanghezhen@163.com

groups significantly improved compared with that at the pre-operation ($P < 0.05$). There was no obvious loss for Cobb angle at the final follow-up in the two groups ($P > 0.05$). The number of patients with adjacent vertebral fracture occurred in the A and B group were 2 and 4, respectively ($P > 0.05$). 【Conclusions】 The “inverted U” distribution of bone cement in the vertebral body is one of the factors that affect the clinical effect of PVP, especially rapid pain relief. In addition, it is very important in the filling of bone cement for the lateral walls and anterior column, and this is an important factor to prevent re-collapse of cemented vertebral body.

Key words: percutaneous vertebroplasty; “inverted U” type; distribution of bone cement

[J SUN Yat-sen Univ (Med Sci), 2018, 39(4): 554-559]

随着人口老龄化,骨质疏松骨折已成为我国面临的重要公共健康问题。骨质疏松椎体压缩骨折(osteoporotic vertebral compression fractures, OVCF)是骨质疏松性骨折最常见的类型,它常引起胸/腰背部疼痛、活动受限,影响患者的日常生活,严重威胁老年人的健康,甚至是致死的一个重要因素^[1]。传统的治疗方法有保守治疗,长期卧床休息,但极易引起褥疮、下肢深静脉血栓等并发症,并且加重骨质疏松,形成恶性循环。近年来,随着椎体成形术(percutaneous vertebroplasty, PVP)的开展,因其能快速止痛,早期下床活动,并且预防椎体再塌陷,已逐渐成为治疗OVCF的首选^[2]。但是我们在临床中发现,每个病人的预后并不尽相同,仍有病人术后疼痛不能完全缓解,或者远期随访出现了伤椎再塌陷。Frank等^[3]发现单侧穿刺致水泥分布在椎体的一侧,极易导致椎体再骨折或塌陷。江晓兵等^[4]发现骨水泥在骨折线内的分布可能是术后止痛的一个重要因素,甚至,它可能是导致渐进性后凸畸形的一个危险因素。另外,多项报道也证实,椎体内的骨水泥分布是伤椎再压缩的潜在危险因素^[5-6]。综合既往研究,我们考虑骨水泥在椎体内的分布可能是影响PVP疗效的一个重要因素。因此,探讨骨水泥在椎体内如何分布才能使PVP术后获得更好的疗效非常重要。在我们的前期研究中,通过低黏度骨水泥的超早期注射治疗OVCF中,发现骨水泥容易在椎体内形成一个“倒U型”分布,这种骨水泥分布在国内外尚未见相关报道。所以,我们回顾性分析这些行PVP并在椎体内形成“倒U型”分布的病人,探讨这种水泥分布对PVP临床疗效的影响。总结分析此类患者,对于OVCF患者行PVP治疗时,骨水泥在椎体内如何分布提供一定的参考。

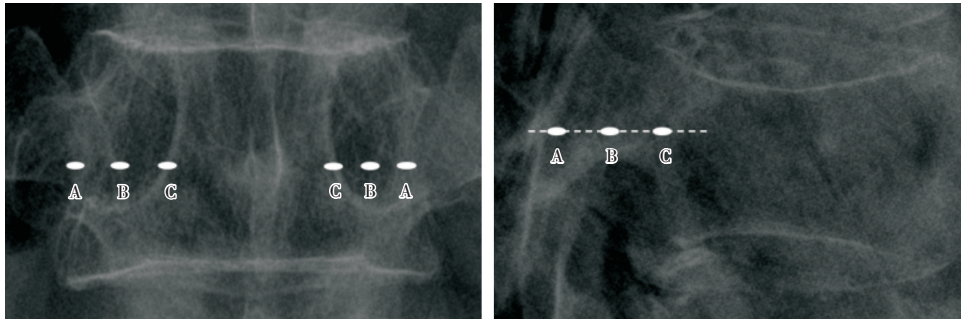
1 材料与方 法

1.1 研究对象

纳入我院从2009年6月至2016年8月间双侧穿刺行低黏度骨水泥(Mendec Spine, Tecres SPA, 意大利)PVP(山东冠龙)手术的病人。纳入标准:①骨密度T值 < -2.50 ;②单一椎体压缩骨折;③疼痛性OVCF,视觉模拟评分(visual analogue scale, VAS)5分以上;④随访至少12个月;⑤压缩骨折不伴有下肢神经症状。排除标准:①血管瘤、转移瘤等非骨质疏松性压缩骨折;②陈旧性压缩骨折;③Kummell病;④未完成随访的病人。本研究得到医院伦理委员会的批准。

1.2 手术方法

患者俯卧位,胸部和骨盆处软枕垫高,腹部悬空,C臂定位双侧椎弓根体表投影处,并标记。①穿刺(双侧):穿刺点选择在平椎体1/2,向前旋转进针,X线侧位进入A点(穿刺点向前延长线与上关节突背侧缘向下延长线交点),正位也在A点(椎弓根外侧缘,3点方向(胸椎),2点方向(腰椎)),继续往前旋转进针,进入侧位B点(A点和椎体后缘连线中点),观察正位穿刺针位于B点(椎弓根外侧缘与内侧缘连线中点),继续旋转进针,侧位达到C点(椎体后缘与A点B点连线的交点),观察正位也进入C点(椎弓根内侧缘,9点方向(胸椎),10点(腰椎)),继续进针,使穿刺针位于椎弓根前方(图1)。②制备水泥:将注射用水和水泥混合,并开始计时,充分震荡、混合1 min,随后将骨水泥注入推杆中。③注射:将带有骨水泥的推杆连接到穿刺装置上,向前送至椎体前缘后方区域,当水泥时间到3 min时,开始注射,先打1/3量的水泥,约0.3 mL,侧位观察椎体前柱水泥

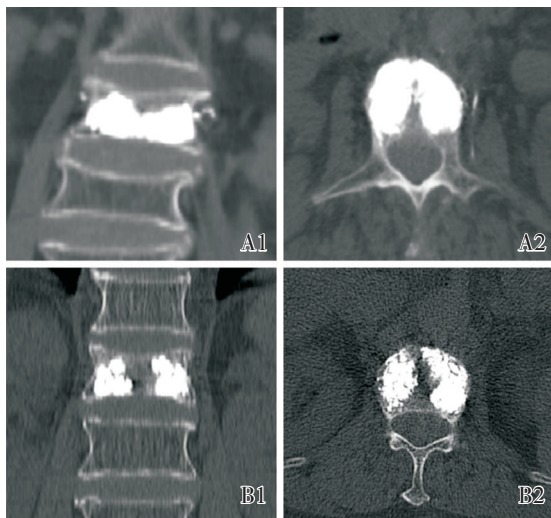


Point A: lateral film, 1/2 of the pedicle (thoracic vertebra), the lower 1/3 of the pedicle (lumbar); anteroposterior film, the lateral border of the pedicle; Point B: lateral film, the midpoint of the connecting line of point A and the posterior margin of vertebral body; anteroposterior film, the midpoint of the connecting line of point A and the medial border of the pedicle; Point C: lateral film, the intersection of the posterior margin of the vertebral body and the extension line of the connecting line of points A and B; anteroposterior film, the medial border of the pedicle.

图1 所有穿刺点的位置

Fig.1 Locations of all puncture points

填充是否充分,如水泥弥散不充分,继续再打 1/3 (0.3 mL),直到前柱弥散充分为止。随后向后退推杆,约 1 cm,然后继续注射骨水泥 1/3 (0.3 mL) 或 1/4 (0.25 mL),观察弥散,如弥散不充分,继续注射骨水泥,直到弥散充分为止。继续后退推杆,约 0.5 cm,再次注射骨水泥,约 1/3 (0.3 mL),根据弥散情况决定是否注射骨水泥,直到骨水泥达到椎弓根前方即停止注射。使骨水泥在椎体内呈倒 U 型分布。待骨水泥凝固后,拔除穿刺设备,敷料包扎切口,返回病房。



A1: coronal CT; A2: transverse CT. Incomplete “inverted U” tape distribution (bone cement is not connected in the anterior edge of the vertebral body); B1: coronal CT; B2: transverse CT

图2 倒U型分布(椎体前缘骨水泥连接)

Fig.2 “Inverted U” tape distribution (bone cement is connected in the anterior edge of the vertebral body)

1.3 分组方法

通过分析术后 X 线及 CT,将完整的“倒 U 型”分布(椎体中央有骨水泥连接)定义为 A 组;将未形成完整的“倒 U 型”分布(椎体中央无骨水泥连接)定义为 B 组(图 2)。

1.4 观察项目与疗效评价指标

收集所有纳入患者的一般基线特点及手术相关数据,包括性别、年龄、体质量、身高、骨密度、住院天数、手术时间、术中出血量、注射水泥量。并记录有无水泥渗漏,有无术后严重并发症。收集患者术前、术后 3 d 及末次随访时的疗效评价指标,包括 VAS、Oswestry 功能障碍指数(Oswestry Disability Index, ODI)、局部后凸(Cobb)角(椎体上、下终板延长线的夹角)和相邻椎体骨折。

1.5 统计方法

采用 SPSS 24.0 统计软件对数据进行统计分析。计量资料均采用均数和标准差($\bar{x} \pm s$)来表达。计量资料组间比较用独立样本 *t* 检验检测两组间的不同,组内的比较用配对 *t* 检验检测不同时间点的差异。计数资料用卡方检验检测组间的差异。 $P < 0.05$ 被认为有统计学意义。

2 结果

2.1 一般资料

83 个患者纳入我们的研究,包括 37 个“倒 U 型”分布和 46 个不完整“倒 U 型”分布的椎体,无患者出现脊髓、神经损伤、感染及脑脊液漏等严重手术并

表1 患者一般基本特点及手术参数
Table 1 Baseline characteristics and surgical parameters of the assessed patients

	Group A (n=37)	Group B (n=46)	P
Patients (female/male)	26/11	31/15	0.779
Age/Years	74.08±8.53	71.24±8.16	0.120
Weight/kg	61.86±10.16	62.59±12.03	0.772
Height/cm	161.16±9.50	162.83±7.99	0.731
BMD(T score)	-3.55±0.81	-3.68±0.88	0.519
Hospital time/d	3.54±0.96	3.67±1.09	0.563
Operation time/min	26.81±7.12	25.87±5.58	0.242
Intraoperative blood loss/mL	12.11±4.52	13.78±3.22	0.062
Injected cement volume/mL	3.83±0.91	3.78±0.74	0.544
Cement leakage [n(%)]	5(13)	8(17)	0.629

发病,随访时间1~2年,平均(1.32±0.23)年。表1呈现了患者的一般基线特征和手术相关参数($P>0.05$)。

2.2 VAS、ODI、局部Cobb角、相邻椎体骨折

两组术前患者疼痛明显,VAS评分较高,术后两组较术前均能明显改善疼痛($P<0.05$),A组较B组改善更明显,VAS评分明显低于B组,差异具有统计学意义($P<0.05$)。末次随访两组VAS评分均较术后3 d有所降低($P<0.05$),但两组间差异无统计学意义($P>0.05$;表2)。所有患者术前ODI均较高,功能障碍明显,两组术前无差异($P>0.05$),术后3 d两组较术前均明显降低($P<0.05$),A组较B组降低更显著($P<0.05$),末次随访两组间差异无统计学意义($P>0.05$;表2)。两组术前局部Cobb角差异无统计学意义($P>0.05$),术后3 d两组局部Cobb角较术前均明显改善($P<0.05$;表2、图3),末次随访两组局部Cobb角较术后3 d均未见明显丢失($P>0.05$),两组间比较无差异($P>0.05$)。A组和B组分别出现了2和

4例相邻椎体骨折,差异无统计学意义($P>0.05$)。

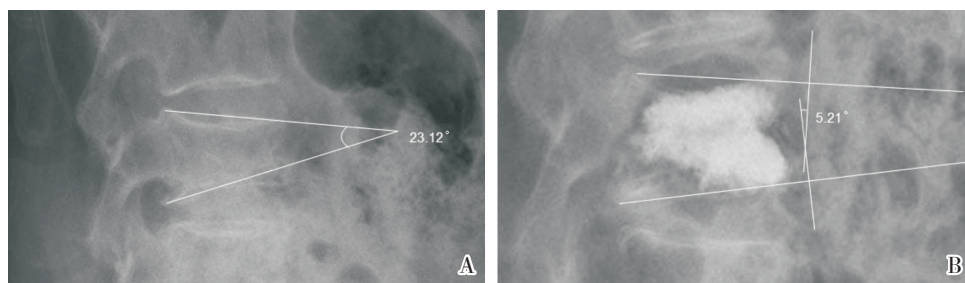
3 讨论

中国已逐步进入老龄化社会,OVCF逐年增多,严重影响老年人的生活质量,它的主要临床表现为后背部疼痛。它的致痛原因可能和以下有关^[7-8]:①骨小梁微骨折刺激痛觉感受器引起疼痛;②骨折椎体不稳定刺激末梢神经引起腰背部肌肉疼痛。目前,PVP已广泛应用于治疗OVCF,它能够快速止痛,早期下床活动,成为了首选的治疗方法。既往研究证实,PVP止痛可能和下列因素相关^[7,9]:①热学因素。骨水泥瞬间产生的高热量,引起椎体内痛觉感受器及末梢神经大量死亡;②化学因素。骨水泥瞬间产生的毒性引起周围神经损伤;③重建脊柱稳定性。骨水泥和骨小梁充分的黏合,形成了稳定架构,从而重建了脊柱的稳定

表2 两组VAS、ODI、局部Cobb角在术前、术后3 d、末次随访的比较
Table 2 Comparison of Cobb angle, VAS and ODI at the pre-operation, post-operation 3 days and final follow-up between the two groups ($\bar{x} \pm s$)

	VAS		ODI/%		Cobb angle/(°)	
	Group A	Group B	Group A	Group B	Group A	Group B
Pre-operation	8.54±0.96	8.50±1.01	67.9±7.2	67.7±9.2	13.5±6.0	13.7±6.0
Post-operation 3 d	1.91±0.59 ¹⁾²⁾	2.37±0.88 ¹⁾	13.4±4.5 ¹⁾²⁾	16.1±5.2 ¹⁾	10.2±4.6 ¹⁾	10.9±4.5 ¹⁾
Final follow-up	1.73±0.56 ¹⁾³⁾	1.71±0.54 ¹⁾³⁾	13.6±4.6 ¹⁾	15.0±4.8 ¹⁾	10.3±4.5 ¹⁾	11.2±4.0 ¹⁾

1) Compared with pre-operation of the same group, $P<0.05$; 2) Compared with group A at the same time point, $P<0.05$; 3) Compared with post-operation 3 d of the same group, $P<0.05$.



A: Cobb angle before operation; B: Cobb angle after operation

图3 椎体成形术的术前后 Cobb 角

Fig.3 Preoperative and postoperative Cobb angle with percutaneous vertebroplasty

性,减少了骨小梁微骨折刺激神经末梢,从而减轻疼痛。但是,我们在临床中发现一部分病人PVP术后却仍残留疼痛,或者疼痛不能完全缓解,会困扰每一位术者。

近年来,有学者从骨水泥注射剂量方向进行了研究,发现骨水泥的注射剂量不是术后疼痛缓解的关键因素,反而随着注射剂量的增多,加大了渗漏的风险^[10]。有研究表明PVP术后止痛的关键因素,在于骨折椎体刚度的提高,刚度的提高可以稳定骨折内骨小梁微骨折的微动,从而起到一个止痛的作用^[11]。Liebschner等^[12]通过有限元分析证实,椎体内15%的骨水泥填充率椎体的刚度即可恢复到骨折前,证实骨水泥占椎体容量的比值比实际骨水泥填充量更为重要。综合以上既往研究,我们认为刚度的提高对于术后止痛尤其重要。在我们的研究中,两组VAS、ODI均较术前明显改善,证实恢复了椎体的刚度,而“倒U型”组较对照组改善更为明显,我们考虑可能和椎体前缘有水泥相连,增加了伤椎的稳定性,从而减少了断裂骨小梁微活动,增加了即刻稳定性,减少了对痛觉感受器的刺激,从而起到了更加优异的止痛效果。而随着骨折椎体的愈合,伤椎更加稳定,末次随访时两组差别不大。而有学者通过研究证实椎体内骨水泥是否弥散于骨折线区域可能是影响PVP疗效的因素之一^[4,13]。这说明伤椎内相对稳定的内环境对于术后疗效的影响至关重要,而在我们的研究中,骨水泥在伤椎内分布主要在前柱和两侧壁(水泥至双侧椎弓根前方),形成了稳定框架结构,有助于伤椎内环境的稳定,减少微骨折的活动,从而起到了更有效的止痛效果。

术后3d两组局部Cobb角均有所恢复,我们考虑这和PVP手术无关,PVP手术本身不能带来后凸角的减少,而是和术前的复位有关,例如术前

卧床时腰背部垫软枕、或者术中的过伸体位等等,均可能造成局部Cobb角的恢复。末次随访时两组局部Cobb角均未见明显增加,我们考虑可能和水泥在椎体内分布有关。这种过伸性的复位,势必导致伤椎前缘高度的增加,拉伸前柱,这时对于术后椎体再塌陷来说前柱的骨水泥充填尤其重要。Lin等^[14]分析了PVP术后伤椎再塌陷的原因,发现前柱恢复满意的患者,因骨水泥在椎体前缘分布不充分,更容易导致再塌陷。田伟等^[15]也证实了这个观点。“倒U型”分布注重椎体前柱和侧壁的充填,我们的结果显示局部Cobb角术后3d至末次随访未明显丢失,而对照组(未形成完整“倒U型”分布)的椎体也未明显丢失,我们考虑尽管未形成完整的“倒U型”分布,但是对于两侧壁的充填是完整的,前柱也得到了部分的充填(中间部分未充填),从而也可以起到一个强有力的支撑,所以两组末次随访局部Cobb角均未见明显丢失。

既往研究证实,PVP术后再发相邻椎体骨折率高达19.2%^[16]。它除了与自身骨质疏松、水泥渗漏入椎间盘等相关外,还和椎体内水泥分布紧密联系^[17]。Tanigawa等^[18]将骨水泥分布分为团块状和海绵状两组,结果发现团块状组相邻骨折再发生率明显高于海绵状组。Liebschner等^[12]发现双侧穿刺的骨水泥分布较单侧穿刺相邻椎体骨折发生率低,他认为可能是单侧穿刺的水泥分布不均匀,增加了单侧的载荷传递所致。在我们的研究中,“倒U型”分布组有较低的相邻椎体骨折发生率,我们考虑可能和两侧更对称的水泥分布相关,双侧存在均匀的载荷传递。而对于非完整“倒U型”分布组(对照组),相邻椎体骨折发生率和倒U型分布组并无差异,所以,我们考虑中间有无骨水泥连接不是相邻椎体骨折的危险因素,而是和

骨水泥在椎体内有无对称分布紧密相关。

总之,通过我们的研究发现骨水泥在椎体内呈“倒U型”分布是影响PVP临床疗效的主要因素之一,尤其是在术后疼痛快速缓解方面。另外,骨

水泥在椎体侧壁和前柱的充填非常重要,它是预防椎体再塌陷的重要因素之一。但是,我们的研究也有一定的局限性,它仅仅是一个单中心小样本量研究,并且是回顾性研究,缺乏一定的随机性。

参考文献

- [1] 中华医学会骨质疏松和骨矿盐疾病分会. 原发性骨质疏松症诊疗指南(2017) [J]. 中国全科医学, 2017, 20(32): 1-26.
Chinese Society of Osteoporosis and Bone Mineral Research. Guidelines for the diagnosis and treatment of primary osteoporosis (2017) [J]. Chin Gene Prac, 2017, 20(32): 1-26.
- [2] Rapan S, Batrnek J, Rapan V, et al. Quality of life in patients following vertebroplasty [J]. Open Access Maced J Med Sci, 2017, 5(1): 42-47.
- [3] Frankl J, Hennemeyer C. Vertebral refracture after unipedicular kyphoplasty resulting in lateralized cement distribution [J]. J Vasc Interv Radiol, 2015, 26(12): 1906-1908.
- [4] 江晓兵, 莫凌, 梁德, 等. 骨水泥在椎体骨折线内弥散情况对椎体成形术治疗效果的影响 [J]. 中国脊柱脊髓杂志, 2014, 24(2): 144-149.
Jiang XB, Mo L, Liang D, et al. The effect of distribution of bone cement in the fracture lines on the outcome of percutaneous vertebroplasty [J]. Chin J Spine Spinal Cord, 2014, 24(2): 144-149.
- [5] Kim JM, Shin DA, Byun D-H, et al. Effect of bone cement volume and stiffness on occurrences of adjacent vertebral fractures after vertebroplasty [J]. J Korean Neurosurg Soc, 2012, 52(5): 435-440.
- [6] Sun YC, Teng MM, Yuan WS, et al. Risk of post-vertebroplasty fracture in adjacent vertebral bodies appears correlated with the morphologic extent of bone cement [J]. J Chin Med Assoc, 2011, 74(8): 357-362.
- [7] Barr JD, Barr MS, Lemley TJ, et al. Percutaneous vertebroplasty for pain relief and spinal stabilization [J]. Spine (Phila Pa 1976), 2000, 25(22): 923-928.
- [8] Francis RM, Aspray TJ, Hide G, et al. Back pain in osteoporotic vertebral fractures [J]. Osteoporos Int, 2008, 19(7): 895-903.
- [9] Furtado N, Oakland RJ, Wilcox RK, et al. A biomechanical investigation of vertebroplasty in osteoporotic compression fractures and in prophylactic vertebral reinforcement [J]. Spine (Phila Pa 1976), 2007, 32(17): E480-487.
- [10] Kaufmann TJ, Trout AT, Kallmes DF. The effects of cement volume on clinical outcomes of percutaneous vertebroplasty [J]. AJNR Am J Neuroradiol, 2006, 27(9): 1933-1937.
- [11] Belkoff SM, Mathis JM, Jasper LE, et al. The biomechanics of vertebroplasty. The effect of cement volume on mechanical behavior [J]. Spine (Phila Pa 1976), 2001, 26(14): 1537-1541.
- [12] Lieschner MA, Rosenberg WS, Keaveny TM. Effects of bone cement volume and distribution on vertebral stiffness after vertebroplasty [J]. Spine (Phila Pa 1976), 2001, 26(14): 1547-1554.
- [13] 俞武良, 陆建猛, 韦勇力, 等. 经皮椎体成形术中椎体内骨水泥分布范围对疗效的影响 [J]. 中国矫形外科杂志, 2015, 23(20): 1836-1840.
Yu WL, Lu JM, Wei YL, et al. Department of spinal surgery influence of bone cement distribution in injured vertebra on clinical results in percutaneous vertebroplasty [J]. Chin Orthop J, 2015, 23(20): 1836-1840.
- [14] Lin WC, Lee YC, Lee CH, et al. Refractures in cemented vertebrae after percutaneous vertebroplasty: A retrospective analysis [J]. Eur Spine J, 2008, 17(4): 592-599.
- [15] 田伟, 韩骁, 刘波, 等. 经皮椎体后凸成形术后骨水泥分布与手术椎体再骨折的关系 [J]. 中华创伤骨科杂志, 2012, 14(3): 211-215.
Tian W, Han X, Liu B, et al. Cement distribution pattern and refracture of cemented vertebrae after percutaneous kyphoplasty [J]. Chin J Orthop Trauma, 2012, 14(3): 211-215.
- [16] Lindsay R, Silverman SL, Cooper C, et al. Risk of new vertebral fracture in the year following a fracture [J]. JAMA, 2001, 285(3): 320-323.
- [17] 付兆宗, 陈忠羨, 秦英, 等. 骨水泥分布指数对椎体成形术后症状性邻近节段骨折的影响 [J]. 南方医科大学学报, 2017, 37(7): 947-951.
Fu ZZ, Chen ZX, Qin Y, et al. Low cement distribution index is a risk factor for refracture of the adjacent segments after percutaneous vertebroplasty [J]. J South Med Univ, 2017, 37(7): 947-951.
- [18] Tanigawa N, Komemushi A, Kariya S, et al. Relationship between cement distribution pattern and new compression fracture after percutaneous vertebroplasty [J]. AJR Am J Roentgenol, 2007, 189(6): W348-352.

(编辑 刘清海)